

## BIOMECHANICS OF WRIST INJURIES IN SPORTS

Sherry L. Werner, PhD, and Kevin D. Plancher, MD, MS

Athletic injuries to the wrist are common at all levels of competition. Allieu<sup>1</sup> has estimated that one quarter of all injuries in sports occur to the wrist joint. McCue and colleagues<sup>32</sup> proposed that wrist injuries are common in athletics because the hand is usually in front of the athlete and absorbs contact in most sports, and because the hands are used to some extent in all sports. An athlete uses the hand to deflect and absorb the impact of their opponents, the ground, and balls of various shapes and sizes.

Rettig and Patel<sup>47</sup> suggested that wrist injuries are most common in pubescent and adolescent athletes compared with the adult population. Although Halikis and Taleisnik<sup>21</sup> reported that there is a new level of sophistication in the diagnosis and treatment of soft tissue wrist injuries in athletics, the complicated nature of the joint makes diagnosis and treatment of these injuries difficult. The complex anatomy, closely situated and interrelated structures, and highly dynamic movement patterns of this joint also make it difficult to study from a biomechanical perspective. Thus, little scientific data regarding the wrist in sport are available to assist the clinician.

Proper diagnosis and treatment of wrist injuries are paramount in the sports medicine setting. According to Koman and colleagues,<sup>24</sup> a "failure to diagnose, manage and rehabilitate an athlete's wrist correctly may result in unnecessary delays in that athlete's return to practice or competition or in permanent reduction in his or her competitive performance." In addition, misdiagnosis or lack of appropriate treatment may result in irreparable damage, thus limiting even activities of daily living. The intent of this article is to review basic anatomy and biomechanics of the wrist and to focus on wrist biomechanics in athletics to provide the clinician with scientific data to support the diagnosis and treatment of wrist injuries in sports.

---

From the Steadman-Hawkins Sports Medicine Foundation, Vail, Colorado (SLW, KDP); and the Plancher Hand and Sports Medicine Orthopaedic Associates, Stamford, Connecticut (KDP)

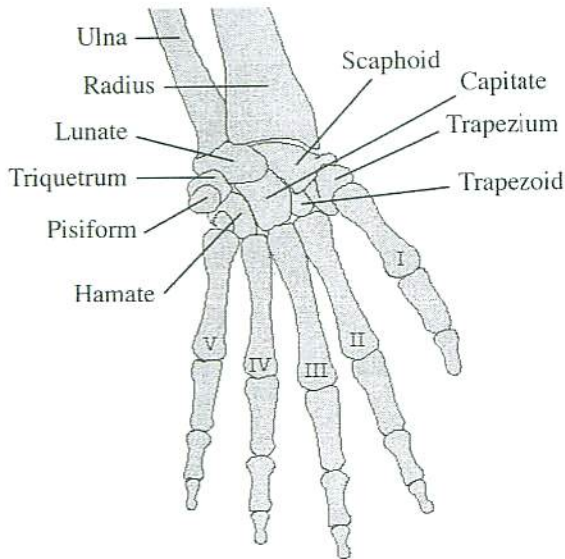


Figure 1. Skeletal anatomy of the wrist joint.

### GENERAL ANATOMY/BIOMECHANICS

The wrist is the distal joint of the upper extremity and functions to position the hand. The relatively large area provided in the cerebral cortex for hand movement emphasizes the importance of the wrist. Motion of this joint allows the hand to be positioned in an unlimited number of orientations to pinch, grasp, or hold an object. This joint is one of the most complex in the human body, comprised of multiple bones and articulations (Fig. 1).

The joint itself is defined as a line passing 3 cm proximal to the radiocarpal space. The distal radius and ulna, carpal-metacarpal joints, and eight carpal bones define the carpal complex (see Fig. 1). Although the wrist is a distinct entity, the fingers clearly attach to the forearm via long flexor and extensor tendons that cross the wrist. Complex articulations between the carpal bones as well as the metacarpals and phalanges are involved in most athletic motions. Thus, although not discussed, the role of the hand and fingers are paramount to wrist biomechanics.

The wrist bones are irregular in shape and are divided into two carpal rows. Radioulnarly, the proximal row consists of the scaphoid, lunate, triquetrum, and pisiform. The distal row consists of the trapezium, trapezoid, capitate, and hamate, again listed radioulnarly. Each of the five metacarpal bones, radioulnarly numbered one through five, consist of a proximal base, a body, and a distal head.

The articular complex of the wrist consists of the midcarpal and radiocarpal joints. The midcarpal joint is located between the proximal and distal rows of carpal bones and may be thought to consist of two (medial and lateral) parts. The lateral component consists of two planar surfaces, the trapezium and trapezoid in contact with the scaphoid. The surfaces of the heads of the capitate and



the hamate, fitting into the concavity of the proximal carpal bones, defines the condyloid, medial component of this articulation.

The radiocarpal joint is ellipsoidal and lies between the radial head and three of the carpal bones in the proximal row. The proximal surfaces of the scaphoid, lunate, triquetrum, and their interosseous ligaments are covered by cartilage to form a continuous surface. The ulna and pisiform do not contribute to this articulation. Proximally, the articular disc of the triangular fibrocartilage complex (TFCC) separates the ulna from the carpus and helps define the radiocarpal joint anatomy. The ulna, with the help of the TFCC and medial carpal bones, carries 20% of the axial load of the forearm. The remaining 80% is borne by the radius and lateral carpus. A transverse convexity on the carpal aspect of the radiocarpal articulation is related to adduction (ulnar deviation) and abduction (radial deviation) motion, and an anteroposterior convexity is related to movements of flexion and extension.

Motion at the wrist is thought to occur in three planes, sagittal (flexion/extension), frontal (radial/ulnar deviation), and transverse (pronation/supination). Circumduction, a combination of flexion/extension and radial/ulnar deviation, takes place in the sagittal and frontal planes simultaneously. Flexion and extension occur at both the midcarpal and radiocarpal joints throughout all ranges of motion (ROMs). On average, 50% to 60% of extension occurs at the radiocarpal and 40% to 50% at the midcarpal joints. Forty percent to 50% of flexion is achieved at the radiocarpal joint and 50% to 60% at the midcarpal joints. The distal radioulnar joint (DRUJ) allows for 150 degrees of rotation (pronation/supination), as the distal radius moves about the ulnar head. The ulnar head translates dorsally with rotation.

Average maximum ranges of motion at the wrist are: 59 degrees of extension, 79 degrees of flexion, 21 degrees of radial deviation, and 38 degrees of ulnar deviation.<sup>50</sup> Palmer and co-workers<sup>39</sup> reported a maximum wrist flexion/extension arc of 130 degrees and a 40-degree arc of radial/ulnar deviation. Although activities of daily living occur in less total ROM than can be achieved, most require wrist extension and ulnar deviation. In addition, 90% of wrist injuries in athletics are compressive and occur in the extended position of the wrist.<sup>15, 26</sup>

Triaxial electrogoniometric studies have revealed that most activities of daily living require 30 degrees of extension to 5 degrees of flexion, 10 degrees of radial deviation, and 15 degrees of ulnar deviation. In other studies, most activities require 40 degrees of extension, 40 degrees of flexion, and a total arc of 40 degrees of radial/ulnar deviation. Information regarding wrist ROM required in various sports is limited. A recent study defined four phases of wrist motion that occur during pitching: cocking, acceleration, deceleration, and recovery. The cocking phase begins with neutral wrist positions and ends in an average of 32 degrees of wrist extension. The acceleration phase follows and is the most explosive, providing for 94 degrees of motion over only 105 msec. At the end of the acceleration phase, the ball is released thus beginning the deceleration phase. Deceleration ends with the wrist in maximal flexion for the cycle. Finally, during recovery, the wrist slowly returns to neutral. Additionally, the average arc of radial and ulnar deviation was calculated to be 27.4 degrees from the end of cocking phase to the end of follow-through.

In a study of free-throw shooting in basketball, the biaxial electrogoniometer was used to analyze wrist range of motion. Ohnishi and associates<sup>37</sup> found that an average of 50 degrees of extension (range, 40 to 56 degrees) and 70 degrees of flexion (range, 48 to 84 degrees) for an arc of 120 degrees was required in the dominant wrist. This is opposed to a total arc of 32 degrees used in the

nondominant extremity. This difference has implications when a surgeon must consider certain surgical or reconstructive procedures in the wrist of a basketball player. A disorder that significantly restricts wrist motion can affect shooting ability in basketball. The average ROM following triscaphoid fusion is similar to that required to shoot a basketball. Wrist ROM also was studied during the three-point shot and was noted to be similar to that in the free throw, which indicated that much of the power for the longer shot most likely is derived from the trunk and legs, as in the pitch in baseball.

A similar study of the golf swing showed that the required ROM of the left wrist averaged 6 to 53 degrees of extension and from 25 degrees of radial to 27 degrees of ulnar deviation. The right wrist ROM averaged 0 to 54 degrees of flexion and 22 degrees of radial and 23 degrees of ulnar deviation. Another study showed that a flexion/extension arc of 103 degrees is required in the right wrist as opposed to 71 degrees in the left wrist. Radioulnar deviation was  $45 \pm 2$  degrees in both wrists, which agrees with the previous study. Advanced players use less flexion/extension on the left but more on the right than average players.

The study of wrist biomechanics in tennis is in its early stages, but certain observations have been made. It has been calculated that, during the service motion, approximately 10% of the force and 15% of the energy involved in the stroke is dissipated across the wrist joint. The power from these strokes emanates primarily from the trunk and lower body musculature and not from the shoulder, elbow and wrist. Maintaining normal biomechanics of the trunk and lower body in these athletes may help prevent wrist injuries.

Using a biaxial flexible goniometer, Tokunaga and Ryu and colleagues (unpublished observations) have quantitated ROM of the wrist during various strokes by players of varying skill levels. They concluded that the service stroke involved the greatest ROM, encompassing an arc of 90 to 100 degrees of flexion/extension. The forehand encompassed a 40-degree excursion and the backhand 37 degrees. They also noted that the wrist was in extension at the time of impact on all strokes.

Furthermore, the wrist was in ulnar deviation at impact in the serve. During both the forehand and forehand volley, the wrist position ranged from 15 to 30 degrees of ulnar deviation. In the backhand and backhand volley, the wrist was in neutral to 2 to 5 degrees of radial deviation.

It was noted that advanced players demonstrate more extension at impact than beginning players. Maximum radial/ulnar deviation occurs more in beginners than in advanced players. Implications of these biomechanical studies may be that ulnar deviation on impact may account for the frequency of ulnar-sided wrist injuries. Also, the limited motion required for strokes may indicate that return to play may be possible following reconstructive wrist procedures that result in limited ROM. Third, these studies may explain the effectiveness of a restricted motion brace, such as a Nirschl brace.

In the future, further studies will help to determine the specific ROM needed for each individual sport, so that wrist function can better be predicted following certain injuries and surgical procedures.

Combinations of wrist flexion/extension and radial/ulnar deviation, and motions of the elbow and forearm, reduce the individual ranges of motion at the wrist joint. Ulnar deviation has a greater ROM when the forearm is supinated, compared with when the arm is in pronation. In general, radial and ulnar deviation ROMs become minimal when the wrist is fully flexed or extended owing to tension in the carpal ligaments. Also, flexion and extension are minimal when the forearm is pronated.



The irregular shapes of the carpal bones cause the wrist joint to be intrinsically unstable. The major extrinsic ligaments are located on the palmar and dorsal margins and act to restrict and coordinate intercarpal/carpal/carpometacarpal motion. The radioscaphocapitate, radiolunotriquetral, radioscapholunate, ulna lunate, and ulna triquetral ligaments, on the palmar surface of the wrist, serve as the main extrinsic stabilizers.<sup>41</sup> The dorsal intercarpal ligament, between the carpal rows, connects the capitate to both the triquetrum and the scaphoid. The radiocapitate and capitotriquetral ligaments are stabilizers of the distal row of carpal bones. The scapholunate and lunotriquetral ligaments, the most commonly injured intrinsic ligaments, connect the bones of the proximal carpal row and provide rotational stability. The ulna triquetral and lunotriquetral ligaments, along with the TFCC, provide stabilization on the ulnar side of the wrist. Ligamentous anatomy and biomechanics have been found to differ between individuals and within individuals for certain ligaments.<sup>18, 24</sup> Ligaments in the palmar and radial quadrants are the weakest.<sup>27</sup>

The main purpose of the ligaments of the wrist is to provide stability in the frontal and sagittal planes. In the frontal plane, the distal surface of the radius faces distally and medially. As the longitudinal muscles pull, the carpus tends to slide proximally and medially, thus the ligamentous structures of the wrist play an important role in the frontal plane. When the wrist is ulnarly deviated to approximately 30 degrees, however, the pull of the muscles now act perpendicular to this plane of slippage. As a result, the bones of the carpus tend to be pushed back into the joint, and the carpus is stabilized. This 30 degrees of ulnar deviation is the natural resting position of the wrist and coincides with the position of maximum stability. When the wrist is radially deviated, the longitudinal pull of the muscles accentuate joint instability and tend to move the carpal bones proximally and medially.

In the sagittal plane, when the wrist is flexed 30 to 40 degrees, the muscular pull tends to displace the carpal bones in a plane perpendicular to the surface of the distal radius, thus tending to stabilize the carpus. In the neutral position, tension is equal in the anterior and posterior ligaments, and the lunate moves closer to the distal radius. In extension, however, the carpal bones tend to be displaced proximally and anteriorly, and the anterior ligaments become critical. This ligamentous tension, which appears to be proportional to the degree of extension, acts to displace the lunate and capitate proximally and posteriorly, thus stabilizing the carpus.

## INJURY MECHANISMS

In 1992, Mirabello and colleagues<sup>35</sup> outlined four major mechanisms of injury to the wrist: throwing, weightbearing, twisting, and impact. Typically, overuse injuries occur in throwing from repetitive wrist flexion/extension and radial/ulnar deviation patterns, and are prevalent in overhead activities like softball, baseball, racquet sports, javelin, water polo, and team handball. In addition, these injuries can occur in sports like weight lifting or gymnastics, from repetitive impact or compressive loads. According to Gill and Micheli,<sup>19</sup> overuse wrist injuries in sports are most common in the adolescent population. Overuse injuries to the wrist include de Quervain tenosynovitis, intersection syndrome, carpal tunnel syndrome, extensor carpi ulnaris subluxation, and tenosynovitis, as well as tendinitis in any of the other wrist and hand tendons.

Weightbearing wrist injuries, like dorsal carpal impingement syndrome, distal radial physis stress syndrome, scaphoid stress fractures, TFCC injury,

dorsal wrist ganglia, compartment syndrome, and intersection syndrome, occur most commonly in sports like gymnastics, wrestling, and weight lifting. These activities require the athlete to endure repetitive, high-compressive forces at the wrist joints. Twisting injuries, which result from forceful rotations of the wrist, can affect joint stability. Rotational injuries can occur in all athletic activities. Most twisting injuries result in impairment at the DRUJ or ulnar carpus.

Impact injuries occur in sports, such as football, rugby, basketball, baseball, softball, and martial arts, and are characterized by direct impact or fall onto the wrist. Examples of these include scaphoid fractures, hamate fractures, ligament injury, scapholunate dissociation, lunotriquetral dissociation, and TFCC tears. Fractures are the most common sports-related wrist injury in the skeletally immature athletic population.<sup>30</sup> Mayfield and colleagues<sup>30</sup> sequentially loaded cadaver wrists in extension, ulnar deviation and then intercarpal supination and produced scapholunate dissociations initially, followed by carpal dislocations. Lunotriquetral injuries result from loading on the ulnar side of the carpus during carpal hyperpronation.<sup>21</sup>

### SPORT-SPECIFIC INJURIES

In 1990, Amadio<sup>2</sup> suggested four categories of sport (hand contact with competitors, hand contact with a ball, stick sports, and other sports), based on hand involvement. To include more sports, we have expanded on the categories set forth by Amadio. Although some sports fit into several categories, depending on the position played, the following three categories of athletics will be discussed: (1) impact sports; (2) racquet, stick, and club sports; and (3) apparatus/external contact sports. This grouping strategy is an attempt to categorize sports based on mechanisms of wrist injury. Table 1 summarizes the three sport categories and the most common wrist injuries associated with each.

**Table 1.** SPORTS, CATEGORIZED BY WRIST INJURY POTENTIAL, AND COMMON WRIST DISORDERS

Category	Common Injuries
Impact sports Basketball, boxing, football, martial arts, rugby, skating, snowboarding, soccer, team handball, volleyball, wrestling	DRUJ dislocation, distal radius fracture, Kienböck's disease, ligament injury, scaphoid fracture, triquetral fracture, vascular injury
Racquet, stick, and club sports Badminton, baseball, cycling, field hockey, golf, ice hockey, racquetball, rowing, skiing, softball, squash, tennis	DRUJ dislocation, carpal tunnel syndrome, dorsal wrist ganglion, hook of hamate fracture, intersection syndrome, ligament injury, de Quervain's syndrome, tendinitis, TFCC injury, ulnar neuropathy, vascular injury
Apparatus/external contact sports Bowling, gymnastics, rock climbing, weightlifting	Carpal tunnel syndrome, distal radial physis stress syndrome, DRUJ dislocation, dorsal impingement syndrome, dorsal wrist ganglion, impaction syndromes, intersection syndrome, ligament injury, de Quervain's syndrome, scaphoid stress fracture, TFCC injury, vascular injury



## Impact Sports

### *Distal Radioulnar Joint Dislocation*

Sports, such as basketball, boxing, football, martial arts, rugby, skating, snowboarding, soccer, team handball, volleyball, and wrestling, fall under this impact category and are susceptible to injuries to the DRUJ. Dislocation of the distal radius from the ulna occurs from wrist hyperpronation, forceful pronation, or repetitive pronation, resulting in a dorsal dislocation of the ulnar head. Typically, this injury occurs during a fall in which the outstretched hand is pronated and ulnarly deviated. Dislocation of the DRUJ is an exaggeration of the normal rolling and sliding motion of the ulnar head toward the sigmoid notch of the radius during pronation.<sup>26</sup> These authors also reported that ice hockey and other contact sport players are susceptible to traumatic DRUJ injury. Repetitive DRUJ damage is seen in tennis, bowling, and gymnastics.

### *Distal Radius Fracture*

Another common fracture in contact sports occurs to the distal radius. In a study of 225 of these sports-related fractures, seen in an orthopedic trauma unit during one 5-year period, Lawson and colleagues<sup>25</sup> reported that approximately 50% occurred in soccer players, 12% in skiers, 9% in dancers, 7% in rugby players, and 6% in ice sports players. Most of the upper-extremity injuries to youth football players are thought to be distal radius fractures.<sup>48</sup> Fractures of the distal radius are also the most common injury to snowboarders.<sup>6</sup> Davidson and Laliotis<sup>11</sup> reported a greater incidence of wrist injuries for snowboarders compared with skiers. Skating fractures are predominantly to the distal radius as well.<sup>5</sup> Typically, these fractures are caused by a fall onto an outstretched hand. A fall onto a hyperextended wrist in radial deviation forces the dorsal rim of the radius and the dorsal scaphoid rim to impact one another.

### *Kienböck's Disease*

A malady common in athletes who practice martial arts is Kienböck's disease. The radius, by extending further than the ulna, subjects the lunate to large compressive and shear forces. Repetitive impact to the hand, or a single traumatic blow, may fracture the lunate. Over time, disruption of the blood supply leads to avascular necrosis of the lunate. The disease has also been reported in volleyball players.<sup>23</sup>

### *Ligament Injury*

Ligament injuries also occur in sports that require contact with an opponent, ball, or other object. Specifically, Linscheid and Dobyns<sup>26</sup> listed football, basketball, rugby, and ice hockey players as susceptible to ligamentous injury. Typically, this type of injury results from a high-energy impact or a fall from a height, but it can be caused by repetitive loading with the wrist in extension. Pure rotational ligamentous injuries may also occur from twisting motions (i.e., tennis or ice hockey).

During a fall, loading usually occurs with the wrist ulnarly deviated and in extension. The integrity of the scapholunate joint is initially compromised, followed by the capitate and distal carpal bones. Instability then progresses from the scapholunate, to the capitolunate, and then to the lunotriquetral joints.<sup>23</sup>

Progressive injury, from carpal dislocations (i.e., perilunate, palmar lunate), to dissociations (i.e., scapholunate, lunotriquetral), and finally frank ligament tears, results from this type of loading pattern.

Scapholunate damage occurs when the scaphoid and lunate tend to spread, as the head of the capitate compresses these bones.<sup>26</sup> The scaphoid inherently tends to flex owing to its oblique position and the loading applied through the scaphotrapeziotrapezoidal joint. Thus, the distal carpus is dislocated dorsally toward the lunate. An injury to the lunotriquetral ligament occurs from loading on the ulnar side of carpus, with carpal hyperpronation. This mechanism requires wrist extension and radial deviation.

#### *Scaphoid Fracture*

Impact sports involve hand contact with an opponent, ball, or the ground, and thus, result in impact injuries to the wrist. Fractures often occur in impact sports (i.e., basketball<sup>31</sup>). Scaphoid fractures are the most common osseous injury to the wrist joint.<sup>24</sup> Scaphoid fractures account for 70% of all carpal fractures.<sup>47</sup> The mechanism of injury is usually a fall on an outstretched hand with the wrist hyperextended.

The scaphoid is the only bone to bridge both the proximal and distal carpal rows, thus making it more susceptible to injury. This carpal bone also has a poor blood supply. Waist fractures of the scaphoid occur as a result of bending forces applied at the distal portion of the bone, with the proximal portion fixed.<sup>36</sup> Essentially, a forced hyperextension of an ulnarly deviated wrist during a fall on an outstretched hand forces the scaphoid against the distal end of the radius, resulting in a scaphoid fracture. This fracture occurs as a result of the shearing forces of the radius.

#### *Triquetral Fracture*

According to Rettig and Patel,<sup>47</sup> the second most common carpal fracture in sports is to the triquetrum. This type of injury is thought to be the result of a fall on an outstretched hand, with the wrist ulnarly deviated. Impingement occurs between the hamate and ulnar styloid, which most typically causes an avulsion fracture of the triquetrum.<sup>52</sup>

#### *Vascular Injury*

Typically, vascular injury results from repetitive impact to the palmar aspect of the wrist and hand. Vascular structures are superficial in the distal upper extremity region, and athletes who are required to absorb repeated impacts to the hand are at risk for this type of injury. Hyperthenar hammer syndrome results from repetitive trauma to the ulnar artery at the wrist and superficial palmar arch. Athletes participating in martial arts, volleyball, and lacrosse have been diagnosed with this syndrome.<sup>43</sup> In addition, Rettig<sup>43</sup> implicates sports with a probability of falls and stick sports as being risky for this type of vascular injury. Spasm, thrombosis, or aneurysm of the ulnar artery may result from hyperthenar hammer syndrome.

### **Racquet, Stick, and Club Sports**

#### *Distal Radioulnar Joint Dislocation*

See "Impact Sports."



### *Carpal Tunnel Syndrome*

Badminton, baseball, cycling, field hockey, golf, ice hockey, racquetball, rowing, skiing, softball, squash, and tennis all involve contact with a striking or guiding implement. Cycling is included in this category owing to the contact of the athlete with the handlebars and the similarity in wrist injuries with the other sports. Carpal tunnel syndrome is the most common compressive neuropathy in sports.<sup>51</sup> This wrist injury is caused by repetitive motions of grasping or extended periods of extension or flexion. The median nerve becomes compressed as it travels deep into the transverse retinacular ligament in the palmar aspect of the wrist.

The mechanical compression and vascular compromise may also result from ulnar nerve shortening caused by prolonged hyperextension. It has been reported that prolonged wrist extension in cyclists has resulted in carpal tunnel syndrome.<sup>7,41</sup> Repeated flexion and extension, and subsequent flexor tenosynovitis, have been suggested as the cause of median nerve compression in tennis.<sup>23</sup> Haas and Meyers<sup>20</sup> reported acute carpal tunnel in rock climbers. An increase in the cross-sectional area of the flexor digitorum superficialis and the flexor digitorum profundus muscles are thought to cause median nerve compression in climbers.<sup>22</sup> These muscles are responsible for transferring power from the forearm to the phalangeal joints to provide finger flexion for gripping edges. A 10% incidence of carpal tunnel was found in climbers under 30 years of age.<sup>48</sup>

### *Dorsal Wrist Ganglion*

According to Rettig and Patel,<sup>47</sup> dorsal wrist ganglion occurs frequently in athletes. Ganglia may be occult or overt and originate from the dorsal scapholunate ligament. Rettig and Patel<sup>47</sup> also reported that 15% of the time the overt injury is linked to a traumatic incident. Ganglia are fluid-filled sacs arising from the wrist joint capsule. Occult dorsal ganglia are responsible for most radial wrist pain in tennis players.<sup>45</sup>

### *Extensor Carpi Ulnaris Tendinitis*

After de Quervain's disease, the extensor carpi ulnaris (ECU) is the second most common site of tendinitis in sports.<sup>47</sup> Rowing, badminton, and squash have been the most common sports to cause tendinitis of the ECU. The forceful wrist flexion motion necessary for the athletic skills involved in these sports and the related stress to the ECU tendon are responsible for this overuse injury. In racquet sports, it is the rapid deceleration, as the racquet strikes the ball, that causes tendinitis.

### *Flexor Carpi Ulnaris Tendinitis*

Flexor carpi ulnaris tendinitis has been diagnosed in squash, badminton, and golf players.<sup>46</sup> Repetitive high-speed impacts with the ball are the mechanism of injury.

### *Hook of Hamate Fracture*

Repetitive stress or impact to the hypothenar eminence can result in a fracture to the hook of the hamate. These injuries can be secondary to an impact from a bat, club, stick, racquet, or a fall. Most often, direct pressure from the

handle of a sports implement against the hook of the hamate causes this type of fracture.<sup>3</sup> For example, when gripped, the butt of a bat in baseball rests above the ulnar and distal aspects of the hamate. During the swinging motion, control may be lost and the hook of hamate can be struck by the butt of the handle of the bat.<sup>12</sup>

#### *Intersection Syndrome*

Intersection syndrome is an inflammatory condition at the intersection of the radial wrist extensors (extensor carpi radialis longus and extensor carpi radialis brevis) and the abductor pollicis longus and extensor pollicis brevis. Most commonly, this overuse syndrome is found in rowers, weight lifters, and squash players. This injury is a peritendinous bursal inflammation that results from repetitive wrist flexion against resistance.

#### *Ligament Injury*

See "Impact Sports."

#### *de Quervain's Syndrome*

Repetitive forceful gripping, coupled with excessive deviation of the wrist, is the cause for de Quervain's syndrome. This malady is a tenosynovitis of the abductor pollicis longus (APL) and the extensor pollicis brevis (EPB).<sup>41</sup> Golfers, squash players, and rowers are most at risk.<sup>23</sup> The injury is a tenosynovitis of the first dorsal compartment and is the most common sight of tenosynovitis. The APL and EPB tendons are restrained by the first dorsal compartment of the wrist and angulate toward their insertions on the thumb. This angulation is accentuated by ulnar deviation, and thus, overuse in sports creates an inflammatory process. During the golf swing, an excessive ulnar deviation of the nondominant thumb, in addition to a forceful grip, causes this syndrome.<sup>44</sup> de Quervain's syndrome is also one of the most common tendon problems in tennis players.<sup>45</sup>

#### *Triangular Fibrocartilage Complex Injury*

Twisting motions in tennis, squash, or ice hockey cause high torsional loads on the TFCC.<sup>13</sup> Typically, the TFCC is injured through a combination of rotation and compression, and these injuries can be acute or overuse in nature. Excessive ulnar deviation causes compression to the TFCC. Thus, sports that require ulnar deviation (i.e., baseball, golf, softball, and tennis) subject the TFCC to high-compressive loads. Acute TFCC tears occur because of axial loading of the distal radius, forearm pronation, and a resulting proximal shift of the radius. Sudden excessive pronation or supination may also result in acute TFCC disruption and subsequent peripheral tears.

The height of the TFCC depends on ulnar variance. The TFCC is narrow when the ulnar head extends beyond its radial articulation, and thicker with an ulna minus variance.<sup>24</sup> In gymnasts, growth of the distal radius tends to be arrested, resulting in an ulnar plus variance.<sup>28</sup> The positive ulnar variance tends to increase compressive TFCC loads, and the combination of impact and torsional stresses in gymnastics can exceed the limits of the TFCC. Dobyns and Gabel<sup>16</sup> reported that TFCC tears are the most common ligament injury in gymnastics.



*Ulnar Neuropathy*

Repetitive concussion of the palmar and ulnar aspects of the wrist and hand are thought to cause a distal ulnar neuropathy. This malady is also called Guyon's canal syndrome. This canal is bordered by the palmar carpal ligament, the transverse retinacular ligament, the pisiform, and the hook of the hamate. Compression of the ulnar nerve may occur as the nerve enters the ulnar tunnel or as it curves around the hook of the hamate.<sup>41</sup> Edema and inflammation of the tissues within the canal, owing to repetitive trauma, cause compression of the ulnar nerve. This compressive neuropathy is found in cyclists<sup>18</sup> and in racquet sports. It is the most common nerve disorder in racquet sports and is thought to be caused by the repetitive gripping and associated impact of the racquet handle.<sup>38</sup> In cycling, prolonged hyperextension may result in a shortening of the ulnar nerve, thus defining another mechanism for this neuropathy.<sup>23</sup>

*Vascular Injury*

See "Impact Sports."

**Apparatus/External Contact Sports***Carpal Tunnel Syndrome*

See "Racquet, Stick, and Club Sports."

*Distal Radial Physis Stress Syndrome*

Athletic activities like gymnastics, rock climbing, and weight-lifting have been categorized together as a result of contact with an external object. As a result, athletes who compete in these sports are at risk for similar injuries to the wrist joint. Weightbearing activities with the wrist extended cause repetitive compression forces, which can lead to stress changes in the distal radial epiphysis in young gymnasts. Repetitive vascular damage occurs. This syndrome may also result from tension associated with bar activities in gymnastics. A 10% incidence of stress-related changes in the distal radial physis was reported for gymnasts by De Smet and colleagues.<sup>14</sup> Vascular damage in the distal radius leads to a positive ulnar variance, which, in turn, leads to increased chance of TFCC injury.

*Distal Radioulnar Dislocation*

See "Impact Sports."

*Dorsal Impingement Syndrome*

Repetitive wrist extension in gymnastics skills, such as handsprings, vaulting, and balance beam maneuvers, causes inflammation in the joint capsule.

*Dorsal Wrist Ganglia*

See "Racquet, Stick, and Club Sports."

*Intersection Syndrome*

See "Racquet, Stick, and Club Sports."

*Ligament Injury*

See "Impact Sports."

*de Quervain's Syndrome*

See "Racquet, Stick, and Club Sports."

*Scaphoid Impaction Syndrome*

Repetitive wrist hyperextension, in floor exercise maneuvers in gymnastics or when resting the bar in the palms of weight lifters' hands, causes the dorsal rim of the scaphoid to be forced against the radius. According to Linscheid and Dobyns,<sup>26</sup> this syndrome may also be caused by a single, traumatic incident, although this mechanism is much less common.

*Scaphoid Stress Fracture*

Stress fractures of the scaphoid have been reported in gymnasts. Although uncommon, this injury results from repeated compressive loads, coupled with wrist extension. When the wrist is in extension, the dorsal articular surfaces are compressed. Additional radial deviation causes the dorsal rim of the radius and dorsal scaphoid rim to impact with one another. The dorsal scaphoid is affected most by these loads.

*Triangular Fibrocartilage Complex Injury*

See "Racquet, Stick, and Club Sports."

*Ulna Impaction Syndrome*

In a neutral frontal position of the wrist, the ulna bears 15% of the load during flexion and extension. With ulnar deviation, the ulnar load increases to 24%, and with pronation is 37%.<sup>17</sup> At the extreme range of wrist extension, the dorsal articular surfaces are compressed. In ulnar deviation, the dorsal triquetrum and hamate are forced toward one another. Repetitive movements of pronation and ulnar deviation during weightbearing cause ulna impaction syndrome.

This injury is most frequently seen in gymnasts. The pommel horse apparatus seems to be the mechanism for male gymnasts, as the ulna and triquetrum are impacted. Markolf and colleagues<sup>29</sup> measured forces between the hand and the horse and found loads up to two times body weight, and loading rates in excess of five times body weight per second. These upper-extremity forces are similar to those found for ground reaction forces in running. For female gymnasts, vaulting causes similar loads.<sup>28</sup>



*Vascular Injury*

See "Impact Sports."

**References**

1. Allieu Y: The sportsman's hand. In Tubiana R (ed): *The Hand*, vol 2. Philadelphia, WB Saunders, 1988
2. Amadio PC: Epidemiology of hand and wrist injuries in sports. *Hand Clin* 6:379-381, 1990
3. Bishop AT, Beckenbaugh RD: Fracture of the hamate hook. *J Hand Surg* 13:135-139, 1988
4. Bryan RS, Dobyns JH: Fractures of the carpal bones other than lunate and navicular. *Clin Orthop Rel Res* 149:107-111, 1980
5. Callé SC, Eaton RG: Wheels-in-line roller skating injuries. *J Trauma* 35:946-951, 1993
6. Callé SC, Evans JT: Snowboarding trauma. *J Pediatr Surg* 30:791-794, 1995
7. Collins K, Storey M, Peterson K, et al: Nerve injuries in athletes. *Physician Sports Med* 16:92-96, 1988
8. Corso SJ, Savoie FH, Geissler WB, et al: Arthroscopic repair of peripheral avulsions of the triangular fibrocartilage complex of the wrist: A multi-center study. *Journal of Arthroscopic and Related Surgery* 13:78-84, 1997
9. Culver JE, Anderson TE: Fractures of the hand and wrist in the athlete. *Clin Sports Med* 11:101-128, 1992
10. Culver JE: Fractures of the hand and wrist. *Clin Sports Med* 9:85-109, 1990
11. Davidson TM, Laliotis AT: Snowboarding injuries. A four-year study with comparison with alpine ski injuries. *Western Journal of Medicine* 164:231-237, 1996
12. Dautel G, Merle M: Chondral lesions of the midcarpal joint. *Journal of Arthroscopic and Related Surgery* 13:97-102, 1997
13. Dell PC: Traumatic disorders of the distal radioulnar joint. *Clin Sports Med* 11:141-159, 1992
14. De Smet L, Albrecht C, Lefevre J, et al: Gymnast wrist: An epidemiological survey of ulnar variance and stress changes of the radial physis in elite female gymnasts. *Am J Sports Med* 22:846-850, 1994
15. Deyerle WM: Athlete injuries of the upper extremities. *Clin Orthop* 23:84-89, 1962
16. Dobyns JH, Gabel GT: Gymnast's wrist. *Hand Clin* 6:493-505, 1990
17. Ekenstam FW, Palmar AK, Glisson RR: The load on the radius and ulna in different positions of the wrist and forearm: a cadaveric study. *Acta Orthop Scandinavica* 55:363-365, 1988
18. Frontera WR: Cyclists palsy: Clinical and electrodiagnostic findings. *Br J Sports Med* 17:91-93, 1983
19. Gill TJ, Micheli LJ: The immature athlete: Common injuries and overuse syndromes of the elbow and wrist. *Clin Sports Med* 6:196-203, 1996
20. Haas JC, Meyers MC: Rock climbing injuries. *Sports Med* 20:199-205, 1995
21. Halikis MN, Taleisnik J: Soft-tissue injuries of the wrist. *Clin Sports Med* 15:235-259, 1996
22. Holtzhausen L-M, Noakes TD: Elbow, forearm, wrist and hand injuries among sport rock climbers. *Clin J Sports Med* 6:196-203, 1996
23. Howse C: Wrist injuries in sport. *Sports Med* 17:163-175, 1994
24. Koman LA, Mooney JF, Poehling GG: Fractures and ligamentous injuries of the wrist. *Hand Clin* 6:477-491, 1990
25. Lawson GM, Hajducka C, McQueen MM: Sports fractures of the distal radius-epidemiology and outcome. *Injury* 26:33-36, 1995
26. Linscheid RL, Dobyns JH: Athletic injuries of the wrist. *Clin Orthop* 198:141-151, 1985
27. Logan SE, Mowak MD, Gould PL: Biomechanical behavior of the scapholunate ligament. *Biomed Sci Instrum* 22:81-88, 1986
28. Mandelbaum BR, Bartolozzi AR, Davis CA, et al: Wrist pain syndrome in

- gymnasts—pathogenic, diagnostic, and therapeutic considerations. *Am J Sports Med* 17:305-317, 1989
29. Markolf KL, Shapiro MS, Mandelbaum BR, et al: Wrist loading patterns during pommel horse exercises. *J Biomech* 23:1001-1011, 1990
  30. Mayfield JK, Johnson RP, Kilcoyne RK: The ligaments of the human wrist and their functional significance. *Anat Rec* 186:417-428, 1976
  31. McClelland SJ, Fithian DC: Ipsilateral carpal, metacarpal and ankle fractures resulting from an attempted basketball slam-dunk. *Am J Sports Med* 16:544-546, 1988
  32. McCue FC, Baugher WH, Kulund DN, et al: Hand and wrist injuries in the athlete. *Am J Sports Med* 7:275-286, 1979
  33. Micheli LJ, Smith AD: Injury recognition and evaluation: upper extremity. In Cantu RC, Micheli LJ (eds): *ACSM's Guidelines for the Team Physician*. Malvern, PA, Lea & Febiger, 1991, pp 163-171
  34. Mino DE, Palmer AK, Levinsohn EM: The role of radiography and computerized tomography in the diagnosis of subluxation and dislocation of the distal radioulnar joint. *J Hand Surg* 8:23-31, 1983
  35. Mirabello SC, Loeb PE, Andrews JR: The wrist: Field examination and treatment. *Clin Sports Med* 11:1-25, 1992
  36. O'Brien ET: Acute fractures and dislocations of the carpus. *Orthop Clin* 15:237-257, 1984
  37. Ohnishi N, Ryu J, Chung IS, et al: Analysis of wrist motion during basketball shooting, in Nakamura RL, Linscheid RL, Miura T (eds): *Wrist Disorders: Current Concepts and Challenges*. New York, Springer-Verlag, 1992, pp 49-55
  38. Osterman AL, Moskow L, Low DW: Soft-tissue injuries of the hand and wrist in racquet sports. *Clin Sports Med* 7:329-348, 1988
  39. Palmer AK, Werner FW, Murphy D, et al: Functional wrist motion: A biomechanical study. *J Hand Surg (Am)* 10A:39-46, 1985
  40. Plancher KP, Minnich MR: Sports-specific injuries. *Clin Sports Med* 15:207-218, 1996
  41. Plancher KP, Peterson RK, Steichen JB: Compressive neuropathies and tendinopathies in the athletic elbow and wrist. *Clin Sports Med* 15:331-371, 1996
  42. Powell JW: Pros and cons of data gathering mechanisms. In Vinger PF, Hoerner EF (eds): *Sports Injuries: The Unthwarted Epidemic*, ed 2. Littleton, MA, PSG, 1986, pp 28-32
  43. Rettig AC: Neurovascular injuries to the wrists and hands of athletes. *Clin Sports Med* 9:389-417, 1990
  44. Rettig AC: The hand and wrist. In Stover CN, McCarroll JR, Mallon WJ (eds): *The Medical Aspects of Golf*. Philadelphia, PA, Davis, 1994
  45. Rettig AC: Wrist problems in the tennis player. *Med Sci Sports Exerc* 26:1207-1212, 1994
  46. Rettig AC, Adsit WS: Athletic injuries of the hand and wrist. In Griffin LY (ed): *Orthopedic Knowledge Update: Sports Medicine*. Rosemont, IL, American Orthopaedic Society for Sports Medicine, 1994, pp 205-224
  47. Rettig AC, Patel DV: Epidemiology of elbow, forearm, and wrist injuries in the athlete. *Clin Sports Med* 14:289-297, 1995
  48. Rooks MD, Johnston RB, Ensor CD, et al: Injury patterns in recreational rock climbers. *Am J Sports Med* 23:683-685, 1995
  49. Roser LA, Clawson DK: Football injuries in the very young athlete. *Clin Orthop* 69:219-223, 1970
  50. Ryu JR, Cooney WP, Askew LJ, et al: Functional ranges of motion of the wrist joint. *J Hand Surg (Am)* 16A:409-419, 1991
  51. Wood MB, Dobyns JH: Sports-related extraarticular wrist syndromes. *Clin Orthop* 202:93-102, 1986
  52. Zemel NP: Carpal fractures. In Strickland JW, Rettig AC (eds): *Hand Injuries in Athletes*. Philadelphia, WB Saunders, 1992, pp 155-174

*Address reprint requests to*

Sherry L. Werner, PhD  
 Steadman-Hawkins Sports Medicine Foundation  
 181 W. Meadow Drive, Suite 1000  
 Vail, CO 81657